



CLINICAL CASE

Bilingual edition English/Spanish

A case of pyoderma gangrenosum associated to bevacizumab, angiogenesis role in its etiology

Un caso de pioderma gangrenoso asociado a bevacizumab: papel de la angiogénesis en su etiopatogenia

Iván Maray-Mateos, Cristina Álvarez-Asteinza, Mónica Carbajales-Álvarez, Ana Lozano-Blázquez

Pharmacy Department, Hospital Universitario Central de Asturias, Oviedo. Spain.

Author of correspondence

Iván Maray Mateos
UGC Farmacia
Hospital Universitario Central de Asturias
Avda. Roma, s/n
33011 Oviedo. Spain.

Email:
ivanmaraymateos@gmail.com

Received 6 April 2021;
Accepted 24 June 2021.
Early Access date (09/16/2021).
DOI: 10.7399/fh.11705

How to cite this paper

Maray-Mateos I, Álvarez-Asteinza C, Carbajales-Álvarez M, Lozano-Blázquez A. A case of pyoderma gangrenosum associated to bevacizumab, angiogenesis role in its etiology. *Farm Hosp.* 2021;45(6):340-1.

Introduction

Pyoderma gangrenosum (PG) is an inflammatory neutrophilic dermatosis. The incidence of the condition is 3-10 cases per million population a year and is most common among adults between 30 and 50 years of age¹. There are several kinds of PG, the best known one being ulcerative PG, occurring mostly in the lower limbs. Ulcerative PG is typically accompanied by a rapid progression of ulcerative lesions with purple margins¹.

Colorectal cancer (CRC) accounts for 10% of all cancers diagnosed every year. Systemic treatment of the metastatic disease consists in a combination of chemotherapy with targeted therapies (vascular endothelial growth factor [VEGF] and epidermal growth factor receptor [EGFR] inhibitors)².

Bevacizumab belongs in the angiogenic drug class. It is a humanized monoclonal antibody that binds to VEGF-A, preventing its interaction with the VEGF-e receptor; inhibiting the cell signaling pathway, which would result in neovascularization of the tumor; and inducing apoptosis of the cancer cells. Adverse events caused by bevacizumab include hypertension, proteinuria, gastrointestinal perforation, hemorrhage, and thrombosis. It may also hinder wound healing and may induce the formation of lesions.

Although there are no reports in the literature describing the relationship between the appearance of PG and angiogenesis, PG has been diagnosed in patients treated with inhibitors of tyrosine kinase, an enzyme that is closely linked to angiogenesis³ (Figure 1).

Eleven reports have to date been published on the EudraVigilance website on the occurrence of PG that implicate bevacizumab as the potential culprit⁴. This paper is, to the best of our knowledge, the first comprehensive description of a case of PG in a patient treated with bevacizumab for CCR.

Description of the case

The patient was a 69-year-old male, with no significant medical history, who had been operated in 2013 for a stage II (T4, N0, M0) sigmoid colon adenocarcinoma. In October 2018, he was reoperated for a local recurrence. In the face of the persistence of the disease, in December 2018 it was decided that the patient be administered palliative systemic treatment with fluorouracil + oxaliplatin (FOLFOX6) + panitumumab. In June 2019, in view of the progression of the disease, a second line of chemotherapy was indicated with capecitabine + bevacizumab at a dose of 1,000 mg/m² and 7.5 mg/kg, respectively.

The patient underwent six cycles, which were well tolerated and succeeded in keeping the disease at bay. However, in the course of the sixth cycle he reported atrophic, ulcerative lesions in both lower limbs, which had been developing for 3-4 weeks and did not improve despite treatment with corticosteroids and topical antibiotics. Faced with a potential problem of toxicity, it was decided to discontinue chemotherapy and refer the patient for dermatological assessment.

KEYWORDS

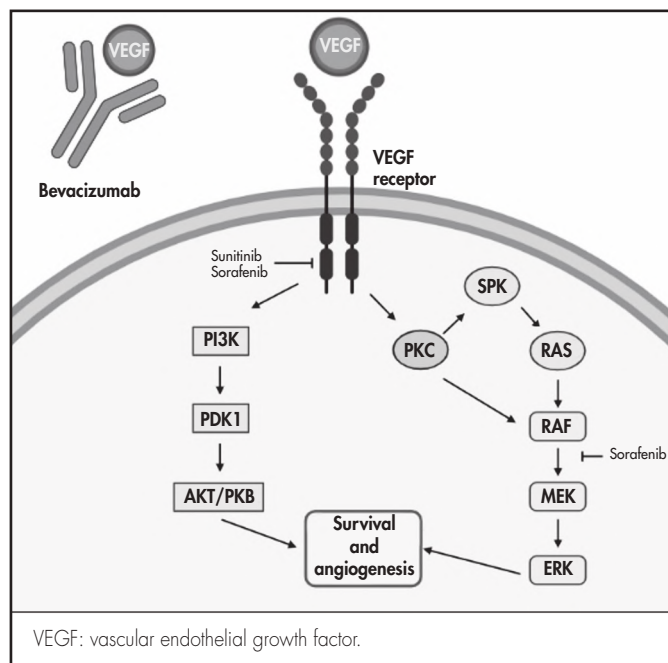
Bevacizumab; Angiogenesis inhibitors;
Pyoderma gangrenosum; Colorectal neoplasms;
Protein kinase inhibitors.

PALABRAS CLAVE

Bevacizumab; Inhibidores angiogénesis;
Pioderma gangrenoso; Neoplasias colorrectales;
Inhibidores de la proteína cinasa.



Los artículos publicados en esta revista se distribuyen con la licencia
Articles published in this journal are licensed with a
Creative Commons Attribution-NonCommercial-ShareAlike 4.0 International License.
<http://creativecommons.org/licenses/by-nc-sa/4.0/>
La revista Farmacia no cobra tasas por el envío de trabajos,
ni tampoco por la publicación de sus artículos.

Figure 1. Cell signaling pathway of angiogenesis.

Dermatological examination revealed multiple ill-smelling, painful ulcers with purple edges in the thighs, knees, elbows, and feet. A biopsy was performed for diagnosis, cultures were obtained, and treatment was started with topical antibiotics and corticosteroids, together with ciprofloxacin and a tapering schedule of oral corticosteroids.

The culture of the ulcers showed growth of *Staphylococcus aureus* and *Enterococcus faecalis*; the material collected by biopsy was not enough for diagnosis. In view of a suspicion of PG, the treatment was supplemented by colchicine/papaverine and dapsone, following the recommendations of the clinical guidelines. The biopsy was repeated¹.

The results of the pathological examination confirmed the diagnosis of PG, the sample showing necrosis and inflammatory cells, with superficial lymphohistiocytic infiltrate and intense neutrophilic infiltrate. Seven months after initiation of immunomodulating treatment, the ulcers healed satisfactorily.

Naranjo's causality algorithm was applied to evaluate the relationship between the adverse reaction and bevacizumab. A score of 3 points (possible association)⁵ was obtained, which led to a decision not to resume treatment with bevacizumab. Capecitabine was reintroduced at one month

from appearance of the lesions and was maintained until progression four cycles later, without reappearance or worsening of PG.

The adverse reaction was reported to the regional pharmacovigilance unit (identification #NRI0590).

Discussion

Although the etiology and pathophysiology of PG are not clearly understood, several factors about the pathogenesis of PG have been elucidated such as an alteration in the patients' immune system, excessive chemotaxis of proinflammatory cytokines, and an abnormal migration of neutrophils¹. As regards the origin of PG, it has been shown that over half of patients with PG present with a concomitant systemic disease, among them solid tumors, with an incidence of 7.4-18%. A systematic review found 8 cases of PG associated to CRC⁶.

Patients with advanced cancer may present with neutrophilia or increased production of interleukin 1, both of them typically found in PG lesions⁷. The studied patient had a neutrophil count of 9,190/mL three weeks before the appearance of the ulcerative lesions.

Chua *et al.* found a relationship between PG and VEGF such that lesions caused by PC usually exhibit an overexpression of VEGF, of hypoxia-inducible factor-2 alpha, and of angiopoietin-2⁸. These are proangiogenic mediators whose synthesis could have been accelerated in response to bevacizumab.

On the other hand, PG cases have been reported in connection with TKIs, particularly sunitinib, imatinib and gefitinib. TKIs inhibit the cell signaling mechanisms involved in tumor growth, among them VEGF-mediated angiogenesis³ (Figure 1). A recent review applied Naranjo's causality algorithm⁵ to all published cases of TKI-related PG and found a probable correlation between TKIs and PG⁹.

The relationship between PG and bevacizumab has only been reported on one occasion¹⁰. This case report described a case of PG where several factors came together: the presence of metastatic CRC, which may lead to PG as a result of a paraneoplastic mechanism, and concomitant treatment with bevacizumab, which interacts with cell signaling mediators, often overexpressed in the lesions that accompany PG.

Although a paraneoplastic syndrome could explain the occurrence of PG, the fact that some of the cases described have been associated with drugs sharing a similar mechanism of action; that overexpression of VEGF has been shown to occur in cases of PG; and that a similar case to ours has been reported in the literature, seems to indicate that bevacizumab could play a role in the development of PG.

Funding

No funding.

Conflict of interest

No conflict of interests.

Bibliography

- Ahn C, Negus D, Huang W. Pyoderma gangrenosum: a review of pathogenesis and treatment. *Expert Rev Clin Immunol*. 2018;14(3):225-33.
- Dekker E, Tanis P, Vleugels J, Kasi P, Wallace M. Colorectal cancer. *Lancet*. 2019;394(10207):1467-80.
- Ara M, Pastushenko E. Antiangiogenic Agents and the Skin: Cutaneous Adverse Effects of Sorafenib, Sunitinib, and Bevacizumab. *Actas Dermosifiliogr*. 2014;105(10):900-12.
- European Medicines Agency. Eudravigilance, European database of suspected adverse drug reactions [Internet] [accessed 06/19/2021]. Available at: <https://www.adrreports.eu/>
- Naranjo CA, Busto U, Sellers EM, Sandor PM, Ruiz I, Roberts EA, *et al.* A method for estimating the probability of adverse drug reactions. *Clin Pharmacol Ther*. 1981;30(2):239-45.
- Kridin K, Cohen A, Amber K. Underlying Systemic Diseases in Pyoderma Gangrenosum: A Systematic Review and Meta-Analysis. *Am J Clin Dermatol*. 2018;19(4):479-87.
- Gupta A, Ortega-Loayza A. Pyoderma gangrenosum: a too often overlooked facultative paraneoplastic disease. *Ann Hematol*. 2019;98(9):2247-8.
- Chua R, Mackelfresh J, Cohen C, Varma V, Fried L, Arbiser J. Disseminated pyoderma gangrenosum: Role for vascular endothelial growth factor and hypoxia inducible factor-2. *J Am Acad Dermatol*. 2009;61(4):730-2.
- Wang JY, French LE, Shear NH, Amiri A, Alavi A. Drug-Induced Pyoderma Gangrenosum: A Review. *Am J Clin Dermatol*. 2018;19:67-77.
- Ellis C, Morrison M, LaFond A, Fivenson D. An interesting case of pyoderma gangrenosum. *J Am Acad Dermatol*. 2016;74(5 Supl):AB292.